

Diagnosis and management of acute deep vein thrombosis: a joint consensus document from the European society of cardiology working groups of aorta and peripheral vascular diseases and pulmonary circulation and right ventricular function

Lucia Mazzolai^{1*}, Victor Aboyans², Walter Ageno³, Giancarlo Agnelli⁴, Adriano Alatri¹, Rupert Bauersachs^{5,6}, Marjolein P.A. Brekelmans⁷, Harry R. Büller⁷, Antoine Elias⁸, Dominique Farge⁹, Stavros Konstantinides^{6,10}, Gualtiero Palareti¹¹, Paolo Prandoni¹², Marc Righini¹³, Adam Torbicki¹⁴, Charalambos Vlachopoulos¹⁵, and Marianne Brodmann¹⁶

¹Division of Angiology, Heart and Vessel Department, Lausanne University Hospital, Ch du Mont-Paisible 18, 1011 Lausanne, Switzerland; ²Department of Cardiology, Dupuytren University Hospital, and, Inserm 1098, Tropical Neuroepidemiology, School of Medicine, 2 avenue martin Luther-King 87042 Limoges cedex, France; ³Department of Clinical and Experimental Medicine, University of Insubria, Via Ravasi 2, 21100 Varese, Italy; ⁴Internal and Cardiovascular Medicine - Stroke Unit, University of Perugia, S. Andrea delle Fratte, 06156 Perugia, Italy; ⁵Department of Vascular Medicine, Klinikum Darmstadt GmbH, Grafenstraße 9, 64283 Darmstadt, Germany; ⁶Center for Thrombosis and Hemostasis, University Medical Center Mainz, Langenbeckstr. 1, 55131 Mainz, Germany; ⁷Department of Vascular Medicine, Academic Medical Center, Meibergdreef 9, 1105 AZ, Amsterdam, The Netherlands; ⁸Cardiology and Vascular Medicine, Toulon Hospital Centre, 54 Rue Henri Sainte-Claire Deville, 83100 Toulon, France; ⁹Assistance Publique-Hôpitaux de Paris, Saint-Louis Hospital, Internal Medicine and Vascular Disease Unit and Groupe Francophone on Thrombosis and Cancer, Paris 7 Diderot University, Sorbonne Paris Cité, 1, Avenue Claude Vellefaux, 75010 Paris, France; ¹⁰Department of Cardiology, Democritus University of Thrace, Greece; ¹¹Cardiovascular Diseases, University of Bologna, Via Albertoni 15, 40138 Bologna, Italy; ¹²Department of Cardiovascular Sciences, Vascular Medicine Unit, University of Padua, Via Nicolò Giustiniani, 2, 35121 Padua, Italy; ¹³Division of Angiology and Hemostasis, Department of Medical Specialties, Geneva University Hospital, Rue Gabrielle Perret-Gentil 4, 1205 Geneva, Switzerland; ¹⁴Department of Pulmonary Circulation and Thromboembolic Diseases, Medical Center for Postgraduate Education, ul Plocka 26, 01-138, Warszawa, Otwock, Poland; ¹⁵Department of Cardiology, Athens Medical School, Profitia elia 24, 14575 Athens, Greece; and ¹⁶Division of Angiology, Medical University Graz, Graz, Austria

Received 18 July 2016; revised 4 November 2016; editorial decision 30 December 2016; accepted 9 January 2017

Introduction

Venous thromboembolism (VTE) incidence increases sharply with age (Figure 1) and appears steady over the last 25 years, despite preventive strategies.¹ Women are more often affected at younger ages; this ratio reverses in the elderly.² Incidence is similar in Blacks but lower in Asians.³ Almost two-thirds of VTE cases are isolated deep vein thromboses (DVTs), and 80% are proximal.⁴

Recent European population studies reported DVT incidence of 70–140 cases/100,000 person-year.⁵

Deep vein thrombosis are mostly secondary to predisposing factors common with pulmonary embolism (PE) (webtable 1).⁶ Distal (below knee) DVTs are more frequently related to transient situations while proximal ones to chronic conditions.⁷ In 25–50% of first DVT episodes, no predisposing factor is identified.

In patients with DVT without PE, short-term mortality rates of 2–5% were reported, more frequent in proximal than distal DVT.⁷ Recurrence risk is high, especially within first 6 months.⁸

Early- and mid-term complications include thrombosis extension, and PE and DVT recurrence (see Supplementary material online, only section).

* Corresponding author. Tel: +41 21 3140750, Fax: + 41 21 3140761, Email: lucia.mazzolai@chuv.ch

The opinions expressed in this article are not necessarily those of the Editors of the *European Heart Journal* or of the European Society of Cardiology.

* Corresponding author. Tel: +41 21 3140750, Fax: + 41 21 3140761, Email: lucia.mazzolai@chuv.ch

Published on behalf of the European Society of Cardiology. All rights reserved. © The Author 2017. For permissions, please email: journals.permissions@oup.com.

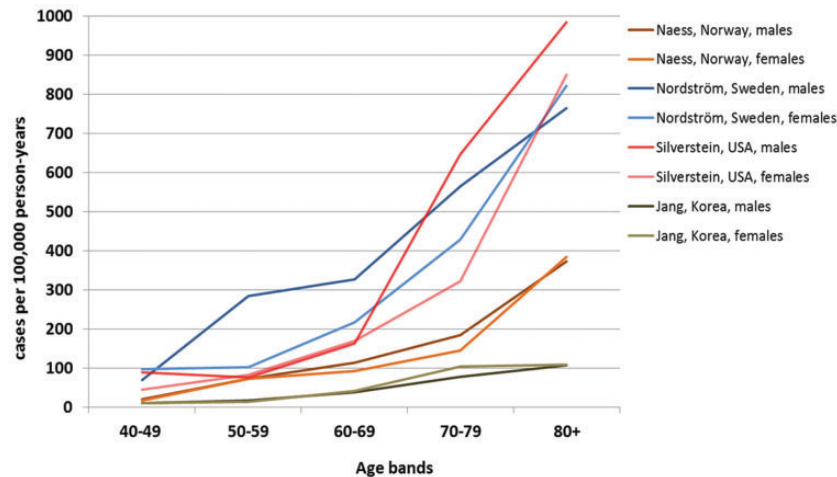


Figure 1 Venous thromboembolism incidence according to age group.

Table 1 Villalta score¹¹

| Symptoms and Clinical signs | None | Mild | Moderate | Severe |
|-----------------------------|----------|----------|----------|----------|
| Symptoms | | | | |
| Pain | 0 points | 1 points | 2 points | 3 points |
| Cramps | 0 points | 1 points | 2 points | 3 points |
| Heaviness | 0 points | 1 points | 2 points | 3 points |
| Paresthesia | 0 points | 1 points | 2 points | 3 points |
| Pruritus | 0 points | 1 points | 2 points | 3 points |
| Clinical signs | | | | |
| Pretibial edema | 0 points | 1 points | 2 points | 3 points |
| Skin induration | 0 points | 1 points | 2 points | 3 points |
| Hyperpigmentation | 0 points | 1 points | 2 points | 3 points |
| Redness | 0 points | 1 points | 2 points | 3 points |
| Venous ectasia | 0 points | 1 points | 2 points | 3 points |
| Pain on calf compression | 0 points | 1 points | 2 points | 3 points |
| Venous ulcer | Absent | Present | | |

Points are summed into a total score (range 0–33). Post Thrombotic syndrome (PTS) is defined by a total score of ≥ 5 or the presence of a venous ulcer. PTS is classified as mild if Villalta score is 5–9, moderate if 10–14, and severe if ≥ 15 or venous ulcer is present.

Long-term complications include post-thrombotic syndrome (PTS), defined as chronic venous symptoms and/or signs secondary to DVT. It represents the most frequent chronic DVT complication, occurring in 30–50% of patients within 2 years after proximal DVT.⁹ In 5–10% of cases, PTS is severe.⁹ Previous ipsilateral DVT, proximal location (ilio-femoral > popliteal), and residual veins obstruction are most significant PTS risk factors. Obesity and poor INR control during

the first 3-months treatment are additional independent risk factors.¹⁰

Villalta score is used for PTS diagnosis and treatment evaluation (Table 1).¹¹

Diagnosis

Deep vein thrombosis without pulmonary embolism symptoms

Clinical signs and symptoms are highly variable and unspecific but remain the cornerstone of diagnostic strategy. Symptoms include pain, swelling, increased skin veins visibility, erythema, and cyanosis accompanied by unexplained fever.

Probability assessment and D-dimer testing

Pre-test probability assessment is the first step in the diagnostic algorithm of DVT suspicion (Figure 2). Sensitivity and specificity of clinical symptoms are low when considered individually; however, their combination, using prediction rules, allows pre-test clinical probability classification into two- (DVT unlikely or likely) or three-categories (low-, intermediate-, or high-clinical probability) corresponding to increasing disease prevalence.^{12,13} Wells score has been widely validated and can be applied both to out- and inpatients (Table 2). The experts' panel favours the modified two-level pre-test probability as it is more straightforward.¹⁴

Normal D-dimers render DVT unlikely,¹⁵ however, D-dimers have low specificity. Quantitative ELISA or ELISA-derived assays (>95% sensitivity) allow ruling out DVT in patients with DVT 'unlikely'. Negative ELISA D-dimer can exclude DVT without further testing in 30% of patients,¹⁶ with 3-month thromboembolic risk <1% without treatment.¹³ Quantitative latex-derived and whole-blood agglutination assay have lower sensitivity (85–90%).¹⁷ In patients with 'likely'

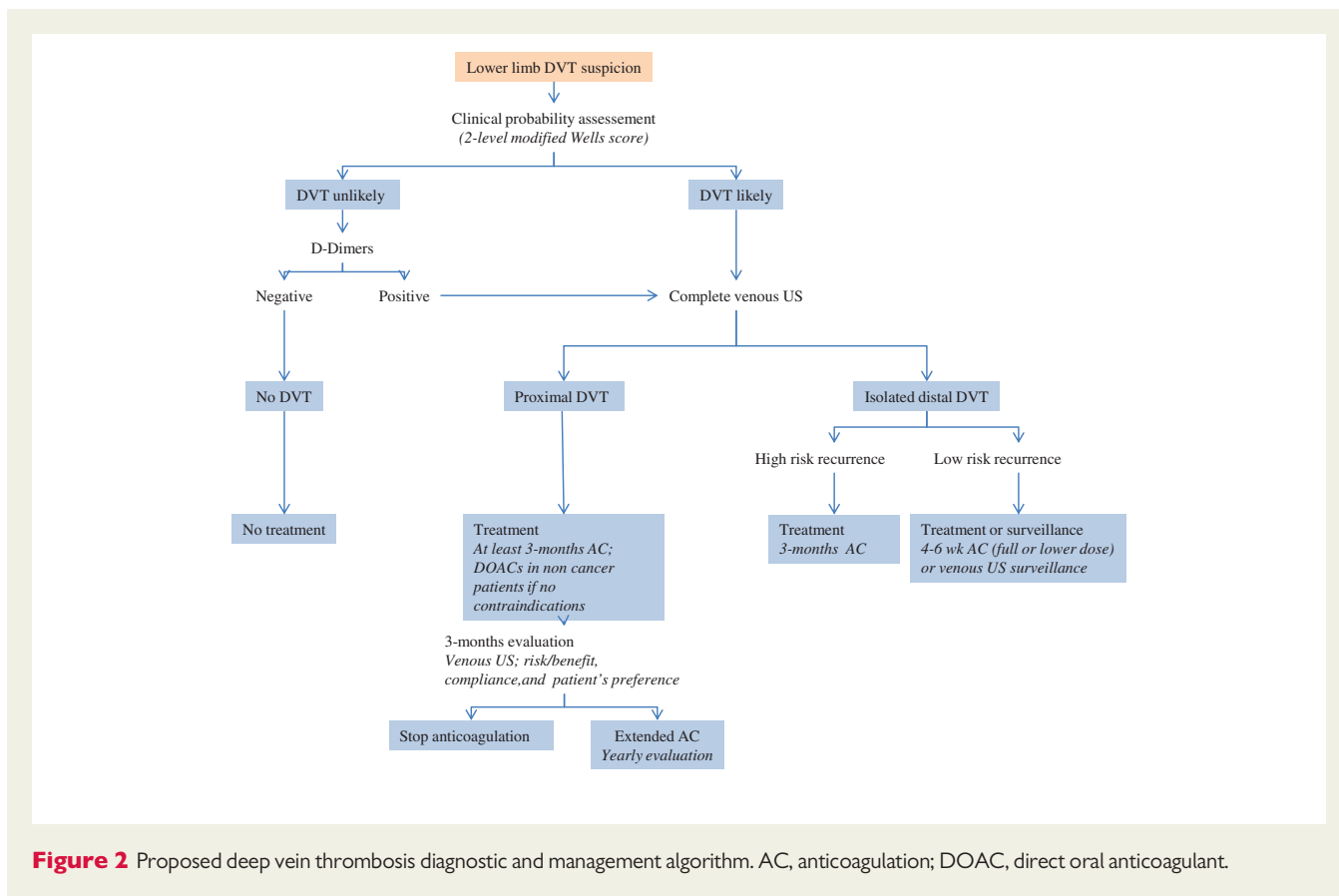


Figure 2 Proposed deep vein thrombosis diagnostic and management algorithm. AC, anticoagulation; DOAC, direct oral anticoagulant.

DVT, D-Dimer testing is not necessary: imaging is required. Therapeutic anticoagulation should be initiated, if not contraindicated, in patients with DVT 'likely' until imaging.

Imaging

Venous ultrasound (VUS) is the first line DVT imaging modality (other imaging: see Supplementary material online, only section). It is based on B-mode, combined or not with color-Doppler US, and power imaging techniques. DVT diagnostic criteria are cross-sectional vein incompressibility, direct thrombus imaging with vein enlargement, and abnormal spectral and color-Doppler flow. VUS can be performed by examining popliteal and common femoral veins only [2-point/2-region compression venous ultrasonography (CUS) or limited CUS], or by extended imaging of inferior vena cava, iliac and femoral veins, and calf veins (whole-leg VUS or complete VUS). There are controversies as to whether explore symptomatic leg only, or both.^{18,19}

In clinically suspected DVT, VUS provides overall sensitivity of 94.2% for proximal, and 63.5% for isolated distal DVT, with an overall specificity of 93.8%.²⁰ Combination with color-Doppler US increases sensitivity but lowers specificity.²⁰ When DVT is suspected (without PE symptoms), anticoagulation may be safely withheld in patients with a single normal complete VUS. Same is true for limited CUS provided it can be repeated, and integrated within a diagnostic strategy

including clinical probability, and D-dimer assessment.²¹ Overall 3-month VTE incidence rate after negative complete VUS is 0.57%,²² but both methods are reported to be equivalent in randomized trials.^{23,24} Complete VUS may be helpful to explain patient's complaint by providing up to 42% alternative diagnosis.²⁵ Point-of care US performed by emergency physicians using limited CUS has shown good performance (96.1% sensitivity, 96.8% specificity)²⁶ and may be useful if vascular laboratories are not available 24/7, provided its integration in a validated diagnostic strategy.²⁷

In patients with clinically suspected recurrent DVT: comparison of test results with baseline imaging at discontinuation of anticoagulation can safely rule out diagnosis of recurrence.²⁸ A 2- or 4-mm²⁹⁻³¹ increase in vein diameter between two measurements at the common femoral and popliteal veins, after full compression, is the most validated US criterion.

Deep vein thrombosis with pulmonary embolism symptoms

Diagnostic approach is described in corresponding 2014 European Society of Cardiology (ESC) Guidelines.⁶ Proximal DVT confirmation in a normotensive patient with suspected PE essentially confirms VTE and justifies anticoagulation as after formal PE diagnosis. In unstable patients with right ventricular overload but no possibility to confirm PE, CUS showing proximal DVT facilitates initiation of reperfusion

therapy. CUS diagnostic yield is high in the presence of clinical DVT signs.³² Among unselected PE patients, proximal DVT at CUS is found in 1/7 patients.³³ Proximal DVT has high specificity and may justify treatment even if pulmonary CT is negative.⁶ While negative CUS cannot exclude PE, it can justify withholding anticoagulation in patients with non-diagnostic ventilation/perfusion scan and PE-unlikely.^{16,34,35}

In symptomatic patients with isolated sub-segmental PE or incidental asymptomatic PE, concomitant DVT justifies anticoagulation.^{36,37} Deep vein thrombosis imaging may also be useful if secondarily a patient is suspected of VTE recurrence with DVT signs. Moreover, presence of concomitant DVT has been suggested as an independent 30-days death risk factor following PE.³⁸

Table 2 The Wells score^{12,13}

| Clinical variable | Points |
|---|--------|
| Active cancer (treatment ongoing or within previous 6 months or palliative) | +1 |
| Paralysis, paresis or recent plaster immobilization of the lower extremities | +1 |
| Recently bedridden for 3 days or more, or major surgery within the previous 12 weeks requiring general or regional anesthesia | +1 |
| Localized tenderness along the distribution of the deep venous system | +1 |
| Entire leg swelling | +1 |
| Calf swelling at least 3 cm larger than that on the asymptomatic leg (measured 10 cm below the tibial tuberosity) | +1 |
| Pitting edema confined to the symptomatic leg | +1 |
| Collateral superficial veins (non varicose) | +1 |
| Previously documented DVT | +1 |
| Alternative diagnosis at least as likely as DVT | -2 |
| Three-level Wells score | |
| Low | <1 |
| Intermediate | 1–2 |
| High | >2 |
| Two-level Wells score | |
| Unlikely | ≤1 |
| Likely | ≥2 |

Consensus statement: diagnosis

- Clinical prediction rule (two-level modified Wells score) is recommended to stratify patients with suspected lower limb DVT.
- ELISA D-dimer measurement is recommended in 'unlikely' clinical probability patients to exclude DVT.
- Venous US is recommended as first line imaging method for DVT diagnosis.
- Venous CT scan should be reserved to selected patients only.
- Venous US should be proposed also in case of confirmed PE, for initial reference venous imaging, useful in case of DVT recurrence suspicion or further stratification in selected patients.
- Venous US may be considered for further stratification in selected patients with concomitant suspected PE

Initial (first 5–21 days) and long-term (first 3–6 months) phase management

Deep vein thrombosis without pulmonary embolism

Anticoagulation in non-cancer patients

Deep vein thrombosis treatment consists of three phases (Figure 3).³⁹ *Initial treatment* (5–21 days following diagnosis); during this period, patients receive either parenteral therapy and are transited to vitamin K antagonists (VKA) or use high-dose direct oral anticoagulants (DOACs). *Long-term treatment* (following 3–6 months); patients are treated with VKA or DOACs.³⁹ Initial and long-term treatments are mandatory for all DVT patients. Decision of *extended treatment* (beyond first 3–6 months) is based on benefit/risk balance of continued anticoagulation.

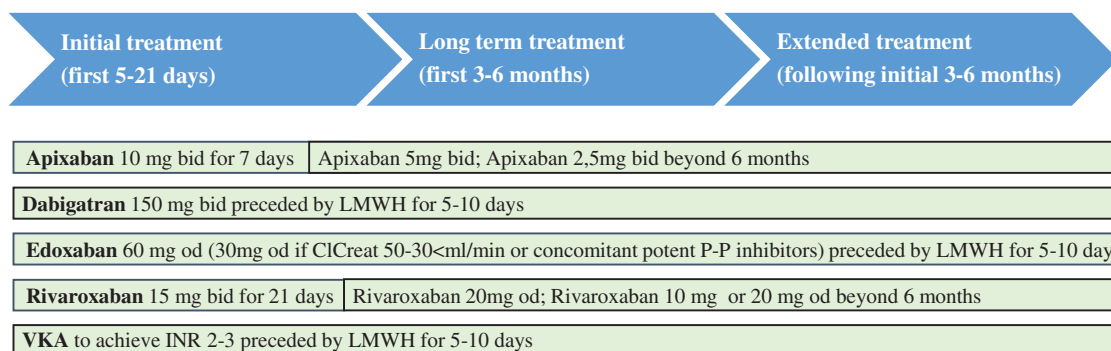


Figure 3 Deep vein thrombosis treatment phases. CrCreat: creatinine clearance; LMWH: low molecular weight heparin; P-P inhibitors: proton pump inhibitors; VKA: vitamin K antagonist.

In patients with severe renal failure (creatinine clearance <30 mL/min), unstable renal function, or high bleeding risk, i.v. unfractionated heparin (UFH) may be preferable (short half-life and protamine sulfate reversibility). Less solid is the evidence in favor of UFH in obese (BMI >40 kg/m²), and underweight patients (<50 kg). Main disadvantage of UFH is its inter-individual dose variability requiring laboratory monitoring and dose adjustment. Additionally, UFH is associated with high risk of heparin-induced thrombocytopenia. For these reasons, low-molecular weight heparin (LMWH) is the parenteral treatment of choice. LMWHs are at least as effective as UFH and probably safer.⁴⁰ Fondaparinux can also be used as parenteral agent.⁴¹ Both LMWH and fondaparinux do not have specific antidote.

Recently, DOACs have emerged as valid options for DVT treatment.³⁹ Dabigatran and edoxaban were studied following initial 7–9 days treatment with a parenteral agent. Apixaban and rivaroxaban were evaluated by the 'single drug approach' (Figure 3).

DOACs have longer elimination half-lives than UFH or LMWH and may accumulate in patients with suboptimal renal (creatinine clearance <30 mL/min) or hepatic function (Child-Pugh class B or C). Patients with poor renal and/or hepatic function, pregnancy/lactation, thrombocytopenia, were excluded from Phase III studies. Patients with active cancer were scarcely represented (3–8% of entire study population).

DOACs are at least as effective as and probably safer than parenteral drug/VKA treatment.⁴² A meta-analysis (27,023 patients) showed similar VTE recurrence rates in patients receiving DOACs or conventional therapy (2.0% vs 2.2%, RR 0.90). Major bleeding (RR 0.61), fatal bleeding (RR 0.36), intracranial bleeding (RR 0.37), and clinically relevant non-major bleeding (RR 0.73) were significantly lower in DOACs-treated patients.⁴² DOACs reversal agents are being investigated. Idaricizumab (Dabigatran reversal agent) is currently available for clinical use.^{43,44}

Thrombolysis/thrombectomy

Early clot removal may prevent, at least partly, PTS development.⁴⁵

Catheter-directed thrombolysis (CDT) is more efficient than systemic lysis, mainly due to less bleeding, as thrombolytic agent is directly administered within the clot. Three major randomized controlled trials compared different CDT modalities on top of anticoagulation and compression, with a control group (anticoagulation and compression only). The CAVENT trial included 209 patients with first-time acute DVT (iliac, common femoral, and/or upper femoral vein).⁴⁶ Adjuvant CDT was associated with a 26% RR PTS reduction over 2 years (41.1% vs. 55.6%, $P=0.04$) compared with anticoagulation alone.⁴⁶ Amount of residual post-CDT thrombus correlated with venous patency rates at 24-months ($P=0.04$). Persistence of venous patency at 6 and 24 months correlated with PTS freedom ($P<0.001$). A 3.2% of patients had major bleed, but there were no intracranial bleeds or deaths. Overall, trial found no differences in long-term (2 years) quality of life between patients with- or without CDT. Results have been confirmed after 5 years follow-up.⁴⁷

Mechanical thrombus removal alone is not successful and needs adjuvant thrombolytic therapy. In PEARL I and II studies, only 5% of patients were treated without thrombolysis.⁴⁸

Up to 83% of patients treated by any catheter-based therapy, need adjunctive angioplasty, and stenting.⁴⁹ Primary acute DVT stenting is not recommended due to lack of data.

Vena cava filter

Vena cava filter may be used when anticoagulation is absolutely contraindicated in patients with newly diagnosed proximal DVT. One major complication is filter thrombosis. Therefore, anticoagulation should be started as soon as contraindications resolve⁵⁰ and retrievable filter rapidly removed. Filter placement in addition to anticoagulation, does not improve survival^{51,52} except in patients with hemodynamically unstable PE or after thrombolytic therapy.⁵³ Increased DVT recurrence has been shown with permanent⁵¹ but not with retrievable filters.⁵²

Compression

Goal of compression is to relieve venous symptoms and eventually prevent PTS.⁵⁴

Elastic compression stockings efficacy has been challenged by the SOX trial.⁵⁵ A total of 806 patients with proximal DVT have been randomized to either 30–40 mmHg or placebo (<5 mmHg) stockings. Cumulative 2 years PTS incidence was similar (52.6% vs 52.3%; HR=1.0). No difference in PTS severity or quality-of-life was observed.⁵⁵ However, compliance definition (stockings wearing for ≥ 3 days/week) was significantly lower than in previous studies (56% vs $\approx 90\%$).⁵⁶ Although role of stockings in PTS prevention may be uncertain, their use remains a reasonable option for controlling symptoms of acute proximal DVT.⁵⁷

Compression associated with early mobilization and walking exercise has shown significant efficacy in venous symptom relieve in patients with acute DVT.⁵⁸ Caution should be used in patients with severe peripheral artery disease.

Home vs in-hospital management

Most patients with DVT may be treated on a home basis (see Supplementary material online, only section).

Deep vein thrombosis with pulmonary embolism

Management of patients with acute PE is described in the 2014 ESC guideline⁶ (summary in the see Supplementary material online, only section).

Isolated distal deep vein thrombosis

Whether isolated distal DVT should be treated with anticoagulation is still debated. A recent trial randomized patients with a first isolated distal DVT to LMWH or placebo for 42 days.⁵⁹ Rate of symptomatic proximal DVT or PE at 42 days was not different between LMWH and placebo (3.3% vs 5.4%); major or clinically relevant non-major bleeding occurred more frequently in the LMWH group (5 vs. 0, $P=0.03$). These data seem to support that not all isolated distal DVT should receive full-dose anticoagulation.

Approach is to anticoagulate full-dose, for at least 3 months, as for proximal DVTs, patients at high-risk VTE (Table 3).⁶⁰ Shorter LMWH treatment (4–6 weeks), even at lower doses, or ultrasound surveillance could be effective and safe in low-risk patients (Table 3).⁶¹ No data are available on DOACs. All patients with acute isolated distal

DVT should be recommended to wear elastic stockings.^{62,63} Follow-up VUS is recommended to monitor thrombosis progression/evolution both in the presence or absence of anticoagulation.

Table 3. Conditions or risk factors for complications after a first isolated distal DVT

| High-risk conditions | Low-risk conditions |
|---|--|
| Previous VTE events | Isolated distal DVT secondary to surgery or other transient risk factors (plasters, immobilization, trauma, long trip, etc.), provided complete mobilization is achieved |
| Males | Isolated distal DVT occurring during contraceptive or replacement hormonal therapy (provided therapy has been interrupted) |
| Age >50 years | |
| Cancer | |
| Unprovoked isolated distal DVT | |
| Secondary isolated distal DVT with persistently hampered mobilization | |
| Isolated distal DVT involving the popliteal trifurcation | |
| Isolated distal DVT involving >1 calf vein | |
| Isolated distal DVT present in both legs | |
| Presence of predisposing diseases (e.g. inflammatory bowel diseases) | |
| Known thrombophilic alterations | |
| Axial vs Muscular isolated distal DVT | |

Incidence of recurrent VTE appears to be similar to that of patients with proximal DVT.^{64,65}

Consensus statement: initial and long-term management:

- Patients with proximal DVT should be anticoagulated for at least 3-months.
- Patients with isolated distal DVT at high-risk of recurrence should be anticoagulated, as for proximal DVT; for those at low risk of recurrence shorter treatment (4–6 weeks), even at lower anticoagulant doses, or ultrasound surveillance may be considered.
- In the absence of contraindications, DOACs should be preferred as first-line anticoagulant therapy in non-cancer patients with proximal DVT.
- Adjuvant CDT may be considered in selected patients with ilio-common femoral DVT, symptoms <14 days, and life expectancy >1 year if performed in experienced centres.
- Primary acute DVT stenting or mechanical thrombus removal alone are not recommended.
- Vena cava filters may be considered if anticoagulation is contraindicated, their use in addition to anticoagulation is not recommended.
- Compression therapy associated with early mobilization and walking exercise should be considered to relieve acute venous symptoms.

Extended phase management (beyond first 3–6 months)

Duration of anticoagulation

Once anticoagulation is stopped, risk of VTE recurrence over years after a first episode is consistently around 30%.⁶⁶ Risk is more than doubled in patients with unprovoked (annual rate >7.0%) vs those with (transient) provoked VTE,⁶⁷ and among the latter in medical rather

Table 4. Risk of recurrence after a first episode of unprovoked VTE

| Risk factors for DVT recurrence | | | |
|---|--|---|---|
| Proximal DVT location | Male sex | Persistence of residual vein thrombosis at ultrasound | |
| Obesity | Non-zero blood group | High D-dimer values | |
| Old age | Early PTS development | Role of inherited thrombophilia is controversial | |
| Clinical prediction rules assessing risk of recurrent VTE after first episode of unprovoked VTE ⁷¹ | | | |
| Score | Vienna prediction model | DASH score | HERDOO-2 |
| Parameters | <ul style="list-style-type: none"> • D-dimer level at 3 weeks and 3, 9, 15, 24 months after stopping anticoagulation • Male sex • VTE location (Distal DVT, Proximal DVT, PE) | <ul style="list-style-type: none"> • Abnormal D-dimer 3–5 weeks after stopping anticoagulation • Male sex • Age <50 years • VTE not associated with oestrogen-progestatif therapy in women | <ul style="list-style-type: none"> • Abnormal D-dimer before stopping anticoagulation • Post thrombotic symptoms (hyperpigmentation, edema and redness) • Age ≥65 years • BMI ≥30 |
| Validation study | Yes | Yes | Yes |
| Commentaries | Different nomograms are available to calculate risk of VTE recurrence at different time | Patients with low score (≤1) have an annual recurrence rate of 3.1% | It is applicable in women only. Women with low score (≤1) have an annual recurrence rate of 1.3% |

than surgical patients.⁶⁸ Patients with a first symptomatic unprovoked DVT are at higher risk of recurrence than those with a first unprovoked PE.⁶⁹ Factors related to DVT recurrence are listed in *Table 4*.

For proximal DVT and/or PE, 3-months anticoagulation is the best option if transient and reversible risk factors were present.⁷⁰ In all other patients, prolonging anticoagulation protects from recurrence (70–90%), but exposes to risk of unpredictable bleeding complications. Decision to discontinue or not anticoagulation should therefore be individually tailored and balanced against bleeding risk, taking also into account patients' preferences. Three clinical prediction rules have been derived and prospectively validated to detect low-recurrence risk patients (*Table 4*).⁷¹ A number of bleeding scores were evaluated, none showed sufficient predictive accuracy or had sufficient validation to be recommended in routine clinical practice.^{72,73}

Continuing indefinite anticoagulation with the same drug administered during the first months is the best option for patients with multiple VTE episodes or strong VTE familial history, those with major thrombophilia, or longstanding medical diseases at high thrombotic risk.⁷⁰ Indefinite anticoagulation can also be considered in patients with first episode of unprovoked VTE, especially in those with severe presentation, provided they are at low bleeding risk.⁷⁰ Finally, discontinuing anticoagulation in non-cancer patients with repeatedly negative D-dimer (before drug interruption, 15, 30, 60, and 90 days following interruption) has proved to be safe in patients with unprovoked proximal DVT provided veins are recanalized or remained stable for 1 year.⁷⁴ However, using moderately sensitive D-dimer assay during and 30 days after stopping anticoagulation, these results were not confirmed in men, and in women with VTE not associated with oestrogen treatment.⁷⁵ Similarly, when measurements were repeated using a quantitative assay, D-dimer testing failed to identify subgroups with very low recurrence rate.⁷⁶

Antithrombotics

Vitamin K antagonists

Four randomized studies evaluated VKA [target international normalized ratio (INR) 2.0–3.0] for VTE extended treatment in patients completing 3-months anticoagulation.^{77–80} Recurrent VTE occurred less in the VKA groups (combined OR 0.07).⁸¹ Bleeding was significantly higher.⁸¹

The ELATE study⁸² randomized patients to conventional intensity (INR 2.0–3.0), or low-intensity (INR 1.5–1.9). Recurrence rate was 0.7 vs 1.9/100 patient-years, respectively (HR 2.8), with no difference in major bleeding. Yet the low-intensity VKA therapy should be discouraged.

Direct oral anticoagulants

Dabigatran (150 mg b.i.d.) was as effective as warfarin and more effective than placebo in preventing recurrent VTE (*Table 5*). Risk of major bleeding was reduced compared with warfarin.⁸³

With Rivaroxaban (20 mg o.d.), risk of VTE recurrence was lower compared with placebo (HR 0.19), while bleeding risk was not increased (*Table 5*).⁸⁴ Standard and lower dose (10 mg od) also significantly reduced risk of recurrence compared to aspirine, without significant increase in bleeding.⁸⁵

VTE recurrence occurred significantly less in standard and lower dose Apixaban (5 and 2.5 mg b.i.d.) vs placebo (*Table 5*). Bleeding did not differ between groups.⁸⁶

Recurrence rates with Edoxaban 60 mg were similar to the warfarin-treated group (post hoc analysis) (*Table 5*).⁸⁷ Major bleeding was lower in the edoxaban group.

Data from Phase IV studies are scarce, but results from XALIA are consistent with observations of rivaroxaban and warfarin.⁸⁸

Aspirin

Two studies investigated aspirin 100 mg vs placebo in patients with idiopathic VTE who completed initial anticoagulation treatment.^{89,90} Pooled HR for VTE recurrence was 0.68 and 1.47 for bleeding.⁹¹

Other

Recent evaluation of Sulodexide vs placebo in patients with unprovoked VTE, who completed standard course of anticoagulation, showed a HR for VTE recurrence of 0.49 ($P=0.02$).⁹² No major bleeding episodes were observed.

Venous occlusion recanalization

Endovascular techniques are available for selected patients with PTS.⁵⁷ Case series and prospective cohort trials suggest that at least some subgroups of PTS patients (CEAP classes 4–6; *Figure 4*) may benefit from addition of endovascular therapy into overall management strategy.

In patients with moderate-to-severe PTS and iliac vein obstruction, endovascular stent placement may be used to restore vein patency. In preliminary studies, stent placement in chronically occluded iliac veins contributed to ulcers healing, PTS symptoms relief, and reduced obstructive venous sequel.⁹³

No randomized controlled trials are available, the largest series found patients with moderate-to-severe PTS to have reduced pain ($P<0.0001$), severe pain (from 41% to 11%), and severe swelling (from 36% to 18%); increased ulcer healing (68%), and reduced venous pressure following recanalization with stent placement.⁹³ Claudication improvement, better outflow fraction, and calf pump function was also observed.⁹⁴

In selected infrequent cases, surgical vein bypass may be an option to relieve venous hypertension.

Follow-up

Patients with DVT should be followed to avoid risk of recurrence as well as DVT and anticoagulation-related complications. Development of renal failure, changes in body weight, or pregnancy that may require anticoagulation adjustment should be monitored. Compliance as well as benefit/risk balance should be assessed regularly. VUS, at anticoagulation discontinuation, is useful in determining baseline residual vein thrombosis.

Consensus statement: extended management:

- Decision to discontinue or not anticoagulation should be individually tailored, balancing risk of recurrence against bleeding risk, taking into account patients' preferences and compliance.
- In the absence of contraindications, DOACs should be preferred as first line anticoagulant therapy in non-cancer patients. Currently

Table 5 Extended secondary prevention of VTE: comparison of results from Phase III trials with direct oral anticoagulants

| Direct oral anticoagulant/trial | Design | n | Treatment regimen | Recurrent VTE or VTE-related death (% of population, HR) | Major bleeding (% of population, HR) | Intracranial hemorrhage (% of population, HR) | Gastrointestinal bleeding (% of population, HR) | Death from any cause (% of population, HR) |
|--|---------------------------------|------|--|---|--|---|---|--|
| Dabigatran RE-MEDY ⁷ | Randomized, double-blind | 2866 | Dabigatran 150 mg b.i.d. vs. warfarin (INR 2.0–3.0) | Dabigatran 150 mg vs. warfarin: 1.8 vs. 1.3 HR 1.44, 95% CI 0.78–2.64 P = 0.01 | Dabigatran 150 mg vs. warfarin: 0.9 vs. 1.8 HR 0.52, 95% CI 0.27–1.02 P = 0.06 | Dabigatran 150 mg vs. warfarin: 0.1 vs. 0.3 No HR reported | Dabigatran 150 mg vs. warfarin: 0.3 vs. 0.6 No HR reported | Dabigatran 150 mg vs. warfarin: 1.2 vs. 1.3 HR 0.90, 95% CI 0.47–1.72 P = 0.74 |
| RE-SONATE ⁸⁴ | Randomized, double-blind | 1343 | Dabigatran 150 mg b.i.d. vs. placebo | P = 0.01 non-inferiority Recurrent or fatal VTE or unexplained death Dabigatran 150 mg vs. placebo: 0.4 vs. 5.6 HR 0.08, 95% CI 0.02–0.25 P < 0.001 for superiority | Dabigatran 150 mg vs. placebo: 0.3 vs. 0 No HR reported P = 1.0 | No intracranial hemorrhages observed | No HR reported | Dabigatran 150 mg vs. placebo: 0 vs. 0.3 No HR reported |
| Rivaroxaban EINSTEIN-Extension ⁸⁵ | Randomized, double-blind | 1197 | Rivaroxaban 20 mg od vs. placebo | Recurrent VTE Rivaroxaban 20 mg vs. placebo: 1.3 vs. 7.1 HR 0.18, 95% CI 0.09–0.39 P < 0.001 | Rivaroxaban 20 mg vs. placebo: 0.7 vs. 0 No HR reported P = 0.11 | No intracranial hemorrhages observed | Rivaroxaban 20 mg vs. placebo: 0.5 vs. 0 No HR reported | Rivaroxaban 20 mg vs. placebo: 0.2 vs. 0.3 No HR reported |
| Apixaban AMPLIFY-Extension ⁸⁶ | Randomized, double-blind | 2486 | Apixaban 5 mg b.i.d. or apixaban 2.5 mg b.i.d. vs. placebo | Apixaban 5 mg vs. placebo: 1.7 vs. 8.8 RR 0.20, 95% CI 0.11–0.34 P < 0.001 | Apixaban 5 mg vs. placebo: 0.1 vs. 0.5 RR 0.25, 95% CI 0.03–2.24 | No intracranial hemorrhages observed | Apixaban 5 mg vs. placebo: 0.1 vs. 0.3 No RR reported | Apixaban 5 mg vs. placebo: 0.5 vs. 1.7 No RR reported |
| Edoxaban Hokusai-VTE post hoc ⁸⁷ | Randomized, double-blind | 7227 | Edoxaban 60 mg qd (or dose reduced 30 mg) vs. warfarin | Edoxaban vs. warfarin: 1.8 vs. 1.9 HR 0.97, 95% CI 0.69–1.37 | Edoxaban vs. warfarin: 0.3 vs. 0.7 HR 0.45, 95% CI 0.22–0.92 | No intracranial hemorrhages observed | Not assessed | Not assessed |
| Data from comparative Phase IV studies | | | | | | | | |
| Rivaroxaban XALIA ⁸⁸ | Prospective, non-interventional | 5142 | Rivaroxaban 15 mg b.i.d. for 3 weeks followed by 20 mg qd vs. heparin/vitamin K antagonist | Rivaroxaban vs. heparin/VKA: 1.4 vs. 2.3 HR 0.91, 95% CI 0.54–1.54 P = 0.72 | Rivaroxaban vs. heparin/VKA: 0.8 vs. 2.1 HR 0.77, 95% CI 0.40–1.50 P = 0.44 | Not assessed | Not assessed | Rivaroxaban vs. heparin/VKA: 0.4 vs. 3.4 HR 0.51 95% CI 0.24–1.07 P = 0.07 |

| CEAP classification and description | |
|---|--|
| 1. Clinical classification | |
| C ₀ : | No visible or palpable signs of venous disease |
| C ₁ : | Telangiectases or reticular veins |
| C ₂ : | Varicose veins |
| C ₃ : | Edema |
| C _{4a} : | Pigmentation and/or eczema |
| C _{4b} : | Lipodermatosclerosis and/or atrophy |
| C ₅ : | Healed venous ulcer |
| C ₆ : | Active venous ulcer |
| C ₇ : | Symptoms, including ache, pain, tightness, skin irritation, heaviness, muscle cramps, as well as other complaints attributable to venous dysfunction |
| C _A : | Asymptomatic |
| 2. Etiologic classification | |
| E _c : | Congenital |
| E _p : | Primary |
| E _s : | Secondary (postthrombotic) |
| E _n : | No venous etiology identified |
| 3. Anatomic classification | |
| A _s : | Superficial veins |
| A _p : | Perforator veins |
| A _d : | Deep veins |
| A _n : | No venous location identified |
| 4. Pathophysiologic classification | |
| P _r : | Reflux |
| P _o : | Obstruction |
| P _{ro} : | Reflux and obstruction |
| P _n : | No venous pathophysiology identifiable |

Figure 4 Chronic venous disorders clinical classification (CEAP).

low-dose apixaban and rivaroxaban have shown their benefit in this setting.

- When VKAs are proposed, they should be administered at conventional intensity regimen (INR 2–3).
- Aspirin may be considered for extended treatment if anticoagulation is contraindicated.
- Endovascular recanalization may be considered in patients with chronic venous occlusion class CEAP 4–6.
- Regular (at least yearly) assessment of compliance and benefit/risk balance should be performed in patients on extended treatment.
- At anticoagulation discontinuation, venous US should be performed to establish a baseline comparative exam in case of recurrence.

Special situations

Upper extremities deep vein thrombosis

Upper extremities DVT (UEDVT) accounts for 10% of all DVTs with an annual incidence of 0.4–1.0/10,000 persons.^{95,96} Incidence rises because of increasing use of central venous catheters, cardiac pacemakers, and defibrillators.^{95,96} Complications are similar, although less frequent, to those of lower limb DVT.^{95,96} About 20–30% of

Table 6 Constans clinical score for UEAD

| Constans score: item | Risk score |
|---|------------|
| Central venous catheter or pacemaker thread | 1 |
| Localized pain | 1 |
| Unilateral edema | 1 |
| Other diagnosis at least as plausible | -1 |

Score ≤1 = Upper extremity DVT unlikely.
Score ≥2 = Upper extremity DVT likely.

Table 7 Khorana decision score in cancer patients

| Khorana score: patient characteristic | Risk score |
|---|------------|
| Site of cancer | |
| Very high risk (stomach, pancreas) | 2 |
| High risk (lung, lymphoma, gynecologic, bladder, testicular) | 1 |
| Pre-chemotherapy platelet count $350 \times 10^9/L$ or more | 1 |
| Hemoglobin level $<10 \text{ g/dL}$ or use of red cell growth factors | 1 |
| Pre-chemotherapy leukocyte count $>11 \times 10^9/L$ | 1 |
| BMI $\geq 35 \text{ kg/m}^2$ | 1 |

Score ≥ 3 = high risk; Score 1–2 = intermediate risk; Score 0 = low risk.

UEDVT are primary comprising those caused by anatomic abnormalities or following sustained physical efforts.⁹⁷ Secondary DVT include venous catheter- and devices-related complications, cancer, pregnancy, and recent arm/shoulder surgery or trauma. Most common clinical presentation includes pain, swelling, and skin discoloration. A clinical decision score has been proposed (Table 6).⁹⁸ D-Dimer showed good negative predictive value in symptomatic DVT.^{99,100} VUS is the first choice exam for diagnosis.¹⁰¹

A diagnostic algorithm, using Constans score, D-dimer, and VUS was proposed (Table 6).¹⁰⁰ Contrast-, CT-, and MR-venography are not recommended for diagnosis but limited to unresolved selected cases.⁹⁶ Anticoagulation is similar to that of lower limb DVT. Thrombolysis is not routinely recommended but limited to selected severe cases. A prognostic score identifying low-risk DVT patients who could be safely treated at home has been proposed but not yet externally validated.¹⁰²

Deep vein thrombosis at unusual sites

Cerebral vein thrombosis

Most common cerebral vein thrombosis (CVT) presentation includes severe headaches, seizures, focal neurological deficits, and altered consciousness.^{103,104} For the diagnosis and treatment refer to the Supplementary material online, only section.

Splanchnic vein thrombosis

Splanchnic vein thrombosis may present as sudden onset of abdominal pain with or without other non-specific abdominal

Table 8 VTE risk factors during pregnancy

| | |
|----------------------------------|---|
| Prior VTE | Preterm delivery |
| Smoking | Pre-eclampsia |
| Varicosis | Caesarean section (specifically in the emergency situation) |
| Hyperemesis | Postpartum infection or hemorrhage |
| severe thrombophilia | Transfusion |
| assisted reproductive technology | Immobilization |
| BMI >30 kg/m ² | Systemic lupus erythematosus |

symptoms.^{105,106} Upper gastrointestinal bleeding or abrupt ascites worsening may occur in cirrhotic patients, lower gastrointestinal bleeding, or acute abdomen may occur in patients with mesenteric vein thrombosis.¹⁰⁵ For the diagnosis and treatment refer to the Supplementary material online, only section.

Deep vein thrombosis and cancer

Cancer patients show four- to seven-fold increased VTE risk (second cause of death). Incidental VTE is increasingly diagnosed and associated with worse overall survival. VTE risk varies from cancer diagnosis through treatment, with annual incidence rate of 0.5–20% according to cancer site and type, metastasis status, treatment (surgery, chemotherapy), use of central venous catheters, hospitalization, and patient-related factor. Risk-assessment models may help stratify individual VTE risk and tailor adequate therapy (Table 7).^{107–109}

Cancer-related VTE is at high risk of recurrence and bleeding during treatment, risk of death increases up to eight-fold following acute VTE compared with non-cancer patients. LMWH is recommended for initial treatment (similar efficacy and higher safety than UFH). Fondaparinux in patients with history of heparin-induced thrombocytopenia, and UFH in case of renal failure are valid alternatives. Vena cava filter and thrombolysis should only be considered on a case-by-case basis. For long-term treatment, superiority of LMWH over short-term heparin followed by VKA is well documented. LMWH used during at least 3 and up to 6 months when compared with VKA significantly reduced VTE recurrence with similar safety profile. After 6 months, termination or continuation of anticoagulation should be individually evaluated: benefit–risk ratio, tolerability, patients' preference, and cancer activity.¹¹⁰

In symptomatic catheter-related thrombosis, anticoagulation is recommended for at least 3-months. LMWHs are suggested although VKAs can also be used (no direct comparison available). Central-vein-catheter can be maintained in place if it is functional, non-infected, and there is good thrombosis resolution. Optimal anticoagulation duration has not been determined, however, 3-months duration seems acceptable in analogy with upper extremity DVT (UEDVT).¹¹⁰

For VTE recurrence under proper anticoagulation (INR, antiXa within therapeutical range), 3 options are recommended: (i) switch from VKA to LMWH in patients treated with VKA; (ii) increase

weight-adjusted dose of LMWH by 20–25%; (iii) vena cava filter use, although no specific results are available for cancer patients.

No direct comparison of DOACs with LMWH is currently available. Nevertheless, data from recent large VTE trials showed non-inferiority in terms of efficacy and safety of DOACs compared with AVK in cancer patients included in the studies.¹¹¹

Deep vein thrombosis in pregnancy

VTE remains the leading cause of maternal mortality in industrialized world.¹¹² VTE risk factors are listed in Table 8. Validity of DVT clinical prediction rules in pregnancy has not yet been tested prospectively.¹¹³ The LEFt clinical score was proposed.¹¹³ Although D-dimers increase during pregnancy, normal values exclude VTE with likelihood similar to non-pregnant women.⁶ VUS is the primary imaging test.^{114,115} Unless contraindicated, anticoagulation should be initiated until objective testing.^{115,116} If VUS is negative but clinical suspicion high, testing should be repeated.^{117,118} Rarely, CT or MRI venography may be considered.

Treatment is based on heparin anticoagulation (no placenta crossing and not significantly found in breast milk).⁶ LMWHs are safe in pregnancy,^{119–121} anti-Xa monitoring, and dose adaptation cannot be recommended routinely, but may be considered in women at extremes of body-weight or renal disease.⁶ Whether initial full dose anticoagulation can be reduced to intermediate dose for secondary prevention during ongoing pregnancy remains unclear.¹²⁰ Dose reduction should be considered for women at high risk of bleeding, osteoporosis, or low VTE recurrence risk.¹¹⁶ Evidence is insufficient to recommend o.d. or b.i.d. LMWH, but b.i.d. may be more suitable perinatally to avoid high anti-Xa levels at time of delivery. Anticoagulation should be continued for at least 6 weeks postnatally and until at least a total of 3 months treatment.¹¹⁷

Consensus statement: DVT management in special situations:

- In case of UEDVT suspicion, venous US is the first choice imaging test.
- Treatment of UEDVT is similar to that of lower limb DVT with regard to anticoagulation.
- LMWH are recommended for acute treatment of CVT.
- LMWH are recommended for acute treatment of splanchnic vein thrombosis.
- LMWH are recommended for initial and long-term treatment in cancer patients.
- In cancer patients, after 6 months, decision of continuation and, if so, the mode of anticoagulation should be based on individual evaluation of the benefit-risk ratio, tolerability, patients' preference, and cancer activity.
- During pregnancy, venous US is recommended as first line DVT imaging test.
- During pregnancy, LMWH is recommended for initial and long-term treatment.
- Anticoagulant treatment should be continued for at least 6 weeks after delivery with a total of 3-months treatment.

Supplementary material

Supplementary material is available at *European Heart Journal* online.

Conflict of interest: Dr. Mazzolai reports personal fees from Bayer Health Care, personal fees from Pfizer - Bristol-Myers Squibb, personal fees from Daiichi-Sankyo, outside the submitted work. Dr. Abovans reports personal fees from Bayer Healthcare, personal fees from Boehringer Ingelheim, personal fees from Daichii-Sankyo, personal fees from Astra-Zeneca, personal fees from Sanofi, personal fees from MSD, personal fees from BMS/Pfizer alliance, personal fees from Novartis, outside the submitted work. Dr. Ageno reports grants and personal fees from Bayer, grants and personal fees from Boehringer Ingelheim, personal fees from Daiichi Sankyo, personal fees from BMS-Pfizer, personal fees from Aspen, outside the submitted work. Dr. Agnelli reports personal fees from Bristol-Myers-Squibb, personal fees from Pfizer, personal fees from Bayer Healthcare, personal fees from Boehringer Ingelheim, personal fees from Daiichi Sankyo, outside the submitted work. Dr. Alatri reports personal fees from Bayer Health Care, personal fees from Pfizer-Bristol-Myers-Squibb, outside the submitted work. Dr. Bauersachs reports personal fees from Bayer Healthcare, Boehringer Ingelheim, Pfizer - Bristol-Myers Squibb, Daichii-Sankyo, outside the submitted work. Dr. Buller reports grants from Sanofi-Aventis, personal fees from Sanofi-Aventis, grants from Bayer HealthCare, personal fees from Bayer HealthCare, grants from Bristol-Myers-Squibb, personal fees from Bristol-Meyers-Squibb, grants from Daiichi Sankyo, personal fees from Daiichi Sankyo, grants from Glaxo SmithKline, personal fees from Glaxo SmithKline, grants from Pfizer, personal fees from Pfizer, grants from Roche, personal fees from Roche, grants from Isis, personal fees from Isis, grants from Thrombogenics, personal fees from Thrombogenics, during the conduct of the study. Dr. ELIAS reports grants from Bayer Pharma, personal fees from Bayer Pharma, grants from Daiichi Sanjma, personal fees from Daiichi Sanjo Pharma, outside the submitted work. Dr Farge reports other from Portola, non-financial support from Leo Pharma, non-financial support from Aspen, non-financial support from Pfizer, outside the submitted work. Dr. Konstantinides reports grants and personal fees from Bayer Health Care, grants and personal fees from Boehringer Ingelheim, grants and personal fees from Daiichi Sankyo, personal fees from Pfizer - Bristol-Myers Squibb, outside the submitted work. Dr. Palareti reports personal fees from Alfa-Wassermann, personal fees from Daiichi-Sankyo, personal fees from Siemens, personal fees from Werfen, outside the submitted work. Dr. Torbicki reports grants and personal fees from Bayer Healthcare, grants from Pfizer, outside the submitted work. Dr. Vlachopoulos reports personal fees from Bayer, reports personal fees from Merck Sharp &Dome, reports personal fees from Angelini, reports personal fees from Pfizer, reports personal fees from Astra Zeneca, reports personal fees from Menarini, reports personal fees from Elpen, reports personal fees from Merck reports personal fees from Serono, reports personal fees from Novartis, reports personal fees from Boehringer-Ingelheim, reports personal fees from OMRON, reports personal fees from Sanofi Aventis, reports personal fees from PharmaSuiss, reports personal fees from Amgen, outside of the submitted work.

References

- Silverstein MD, Heit JA, Mohr DN, Petterson TM, O'fallon WM, Melton LJ III. Trends in the incidence of deep vein thrombosis and pulmonary embolism: a 25-year population-based study. *Arch Intern Med* 1998;**158**:585–593.
- Heit JA. The epidemiology of venous thromboembolism in the community. *Arterioscler Thromb Vasc Biol* 2008;**28**:370–372.
- White RH, Zhou H, Romano PS. Incidence of idiopathic deep venous thrombosis and secondary thromboembolism among ethnic groups in California. *Ann Intern Med* 1998;**128**:737–740.
- White RH. The epidemiology of venous thromboembolism. *Circulation* 2003;**107**(23 Suppl 1):14–18.
- Raskob GE, Angchaisuksiri P, Blanco AN, Buller H, Gallus A, Hunt BJ, Hylek EM, Kakkar A, Konstantinides SV, McCumber M, Ozaki Y, Wendelboe A, Weitz JI. Day ISCFWT. Thrombosis: a major contributor to global disease burden. *Arterioscler Thromb Vasc Biol* 2014;**34**:2363–2371.
- Konstantinides SV, Torbicki A, Agnelli G, Danchin N, Fitzmaurice D, Galie N, Gibbs JS, Huisman MV, Humbert M, Kucher N, Lang I, Lankeit M, Lekakis J, Maack C, Mayer E, Meneveau N, Perrier A, Pruszczyk P, Rasmussen LH, Schindler TH, Svitil P, Vonk Noordegraaf A, Zamorano JL, Zompatori M. Task Force for the D, Management of Acute Pulmonary Embolism of the European Society of Cardiology. 2014 ESC guidelines on the diagnosis and management of acute pulmonary embolism. *Eur Heart J* 2014;**35**:3033–3069.
- Galanud JP, Kahn SR, Khau Van Kien A, Laroche JP, Quere I. [Epidemiology and management of isolated distal deep venous thrombosis]. *La Revue De Médecine Interne/ Fondation Par La Société Nationale Française De Médecine Interne* 2012;**33**:678–685.
- Mearns ES, Coleman CI, Patel D, Saulsberry WJ, Corman A, Li D, Hernandez AV, Kohn CG. Index clinical manifestation of venous thromboembolism predicts early recurrence type and frequency: a meta-analysis of randomized controlled trials. *J Thromb Haemost* 2015;**13**:1043–1052.
- Prandoni P, Kahn SR. Post-thrombotic syndrome: prevalence, prognostication and need for progress. *Br J Haematol* 2009;**145**:286–295.
- Baldwin MJ, Moore HM, Rudarakanchana N, Gohel M, Davies AH. Post-thrombotic syndrome: a clinical review. *J Thromb Haemost* 2013;**11**:795–805.
- Soosainathan A, Moore HM, Gohel MS, Davies AH. Scoring systems for the post-thrombotic syndrome. *J Vasc Surg* 2013;**57**:254–261.
- Wells PS, Hirsh J, Anderson DR, Lensing AW, Foster G, Kearon C, Weitz J, D'ovidio R, Cogo A, Prandoni P. Accuracy of clinical assessment of deep-vein thrombosis. *Lancet* 1995;**345**:1326–1330.
- Wells PS, Anderson DR, Rodger M, Forge M, Kearon C, Dreyer J, Kovacs G, Mitchell M, Lewandowski B, Kovacs MJ. Evaluation of D-dimer in the diagnosis of suspected deep-vein thrombosis. *N Engl J Med* 2003;**349**:1227–1235.
- Geersing GJ, Zuithoff NP, Kearon C, Anderson DR, Ten Cate-Hoek AJ, Elf JL, Bates SM, Hoes AW, Kraaijenhagen RA, Oudegra R, Schutgens RE, Stevens SM, Woller SC, Wells PS, Moons KG. Exclusion of deep vein thrombosis using the Wells rule in clinically important subgroups: individual patient data meta-analysis. *BMJ* 2014;**348**:g1340.
- Righini M, Perrier A, De Moerloose P, Bounameaux H. D-Dimer for venous thromboembolism diagnosis: 20 years later. *J Thromb Haemost* 2008;**6**:1059–1071.
- Perrier A, Desmarais S, Miron MJ, de Moerloose P, Lepage R, Slosman D, Didier D, Unger PF, Patenaude JV, Bounameaux H. Non-invasive diagnosis of venous thromboembolism in outpatients. *Lancet* 1999;**353**:190–195.
- Di Nisio M, Sohne M, Kamphuisen PW, Buller HR. D-Dimer test in cancer patients with suspected acute pulmonary embolism. *J Thromb Haemost* 2005;**3**:1239–1242.
- Le Gal G, Robert-Ebadi H, Carrier M, Kearon C, Bounameaux H, Righini M. Is it useful to also image the asymptomatic leg in patients with suspected deep vein thrombosis? *J Thromb Haemost* 2015;**13**:563–566.
- Galanud JP, Sevestre MA, Genty C, Pernod G, Quere I, Bosson JL. Is it useful to also image the asymptomatic leg in patients with suspected deep vein thrombosis? Comment. *J Thromb Haemost* 2015;**13**:2127–2130.
- Goodacre S, Sampson F, Thomas S, van Beek E, Sutton A. Systematic review and meta-analysis of the diagnostic accuracy of ultrasonography for deep vein thrombosis. *BMC Med Imaging* 2005;**5**:6.
- Agno V, Camporese G, Riva N, Iotti M, Bucherini E, Righini M, Kamphuisen PW, Verhamme P, Douketis JD, Tonello C, Prandoni P. Analysis of an algorithm incorporating limited and whole-leg assessment of the deep venous system in symptomatic outpatients with suspected deep-vein thrombosis (PALLADIO): a prospective, multicentre, cohort study. *Lancet Haematol* 2015;**2**:e474–e480.
- Johnson SA, Stevens SM, Woller SC, Lake E, Donadini M, Cheng J, Labarere J, Douketis JD. Risk of deep vein thrombosis following a single negative whole-leg compression ultrasound: a systematic review and meta-analysis. *JAMA* 2010;**303**:438–445.
- Bernardi E, Camporese G, Buller HR, Siragusa S, Imberti D, Berchio A, Ghirarduzzi A, Verlato F, Anastasio R, Prati C, Piccoli A, Pesavento R, Bova C, Maltempi P, Zanatta N, Cogo A, Cappelli R, Bucherini E, Cuppini S, Noventa F, Prandoni P. Serial 2-point ultrasonography plus D-dimer vs whole-leg color-coded Doppler ultrasonography for diagnosing suspected symptomatic deep vein thrombosis: a randomized controlled trial. *JAMA* 2008;**300**:1653–1659.
- Gibson NS, Schellong SM, Kheir DY, Beyer-Westendorf J, Gallus AS, McRae S, Schutgens RE, Piovella F, Gerdes VE, Buller HR. Safety and sensitivity of two ultrasound strategies in patients with clinically suspected deep venous thrombosis: a prospective management study. *J Thromb Haemost* 2009;**7**:2035–2041.

25. Elias A, Mallard L, Elias M, Alquier C, Guidolin F, Gauthier B, Viard A, Mahouin P, Vinel A, Boccalon H. A single complete ultrasound investigation of the venous network for the diagnostic management of patients with a clinically suspected first episode of deep venous thrombosis of the lower limbs. *Thromb Haemost* 2003;**89**:221–227.
26. Pomeroy F, Dentali F, Borretta V, Bonzini M, Melchio R, Douketis JD, Fenoglio LM. Accuracy of emergency physician-performed ultrasonography in the diagnosis of deep-vein thrombosis: a systematic review and meta-analysis. *Thromb Haemost* 2013;**109**:137–145.
27. Lewiss RE, Kaban NL, Saul T. Point-of-care ultrasound for a deep venous thrombosis. *Glob Heart* 2013;**8**:329–333.
28. Hamadah A, Alwasaidi T, Leg G, Carrier M, Wells PS, Scarvelis D, Gonsalves C, Forgie M, Kovacs MJ, Rodger MA. Baseline imaging after therapy for unprovoked venous thromboembolism: a randomized controlled comparison of baseline imaging for diagnosis of suspected recurrence. *J Thromb Haemost* 2011;**9**:2406–2410.
29. Prandoni P, Cogo A, Bernardi E, Villalta S, Polistena P, Simioni P, Noventa F, Benedetti L, Girolami A. A simple ultrasound approach for detection of recurrent proximal-vein thrombosis. *Circulation* 1993;**88**:1730–1735.
30. Prandoni P, Lensing AW, Bernardi E, Villalta S, Bagatella P, Girolami A. The diagnostic value of compression ultrasonography in patients with suspected recurrent deep vein thrombosis. *Thromb Haemost* 2002;**88**:402–406.
31. Le Gal G, Kovacs MJ, Carrier M, Do K, Kahn SR, Wells PS, Anderson DA, Chagnon I, Solymoss S, Crowther M, Righini M, Perrier A, White RH, Vickars L, Rodger M. Validation of a diagnostic approach to exclude recurrent venous thromboembolism. *J Thromb Haemost* 2009;**7**:752–759.
32. Pollack CV, Schreiber D, Goldhaber SZ, Slattery D, Fanikos J, O'neil BJ, Thompson JR, Hiestand B, Briese BA, Pendleton RC, Miller CD, Kline JA. Clinical characteristics, management, and outcomes of patients diagnosed with acute pulmonary embolism in the emergency department: initial report of EMPEROR (Multicenter Emergency Medicine Pulmonary Embolism in the Real World Registry). *J Am Coll Cardiol* 2011;**57**:700–706.
33. Da Costa Rodrigues J, Alzuphar S, Combesure C, Le Gal G, Perrier A. Diagnostic characteristics of lower limb venous compression ultrasonography in suspected pulmonary embolism: a meta-analysis. *J Thromb Haemost* 2016;**14**:1765–1772.
34. Wells PS, Ginsberg JS, Anderson DR, Kearon C, Gent M, Turpie AG, Bormanis J, Weitz J, Chamberlain M, Bowie D, Barnes D, Hirsh J. Use of a clinical model for safe management of patients with suspected pulmonary embolism. *Ann Intern Med* 1998;**129**:997–1005.
35. Anderson DR, Kahn SR, Rodger MA, Kovacs MJ, Morris T, Hirsch A, Lang E, Stiell I, Kovacs G, Dreyer J, Dennie C, Cartier Y, Barnes D, Burton E, Pleasance S, Skedgel C, O'rouke K, Wells PS. Computed tomographic pulmonary angiography vs ventilation-perfusion lung scanning in patients with suspected pulmonary embolism: a randomized controlled trial. *JAMA* 2007;**298**:2743–2753.
36. Carrier M, Righini M, Wells PS, Perrier A, Anderson DR, Rodger MA, Pleasance S, Le Gal G. Subsegmental pulmonary embolism diagnosed by computed tomography: incidence and clinical implications. A systematic review and meta-analysis of the management outcome studies. *J Thromb Haemost* 2010;**8**:1716–1722.
37. Dentali F, Ageno W, Becattini C, Galli L, Gianni M, Riva N, Imberti D, Squizzato A, Venco A, Agnelli G. Prevalence and clinical history of incidental, asymptomatic pulmonary embolism: a meta-analysis. *Thromb Res* 2010;**125**:518–522.
38. Becattini C, Cohen AT, Agnelli G, Howard L, Castejon B, Trujillo-Santos J, Monreal M, Perrier A, Yusen RD, Jimenez D. Risk stratification of patients with acute symptomatic pulmonary embolism based on presence or absence of lower extremity DVT: systematic review and meta-analysis. *Chest* 2016;**149**:192–200.
39. Becattini C, Agnelli G. Treatment of venous thromboembolism with new anticoagulant agents. *J Am Coll Cardiol* 2016;**67**:1941–1955.
40. Erkens PM, Prins MH. Fixed dose subcutaneous low molecular weight heparins versus adjusted dose unfractionated heparin for venous thromboembolism. *Cochrane Database Syst Rev* 2010;**9**:Cd001100.
41. Buller HR, Davidson BL, Decousus H, Gallus A, Gent M, Piovella F, Prins MH, Raskob G, van den Berg-Segers AE, Cariou R, Leeuwenkamp O, Lensing AW. Subcutaneous fondaparinux versus intravenous unfractionated heparin in the initial treatment of pulmonary embolism. *N Engl J Med* 2003;**349**:1695–1702.
42. van Es N, Coppens M, Schulman S, Middeldorp S, Buller HR. Direct oral anticoagulants compared with vitamin K antagonists for acute venous thromboembolism: evidence from phase 3 trials. *Blood* 2014;**124**:1968–1975.
43. Pollack CV, Jr., Reilly PA, Eikelboom J, Glund S, Verhamme P, Bernstein RA, Dubiel R, Huisman MV, Hylek EM, Kamphuisen PW, Kreuzer J, Levy JH, Sellke FW, Stangier J, Steiner T, Wang B, Kam CW, Weitz JI. Idarucizumab for Dabigatran reversal. *N Engl J Med* 2015;**373**:511–520.
44. Siegal DM, Curnutte JT, Connolly SJ, Lu G, Conley PB, Wiens BL, Mathur VS, Castillo J, Bronson MD, Leeds JM, Mar FA, Gold A, Crowther MA. Andexanet Alfa for the reversal of factor Xa inhibitor activity. *N Engl J Med* 2015;**373**:2413–2424.
45. Alesh I, Kayali F, Stein PD. Catheter-directed thrombolysis (intrathrombus injection) in treatment of deep venous thrombosis: a systematic review. *Catheter Cardiovasc Interv* 2007;**70**:143–148.
46. Enden T, Haig Y, Klow NE, Slagsvold CE, Sandvik L, Ghanima W, Hafsahl G, Holme PA, Holmen LO, Njaastad AM, Sandbaek G, Sandset PM, CaVen TSG. Long-term outcome after additional catheter-directed thrombolysis versus standard treatment for acute iliofemoral deep vein thrombosis (the CaVenT study): a randomised controlled trial. *Lancet* 2012;**379**:31–38.
47. Haig Y, Enden T, Grotta O, Klow NE, Slagsvold CE, Ghanima W, Sandvik L, Hafsahl G, Holme PA, Holmen LO, Njaastad AM, Sandbaek G, Sandset PM. Post-thrombotic syndrome after catheter-directed thrombolysis for deep vein thrombosis (CaVenT): 5-year follow-up results of an open-label, randomised controlled trial. *Lancet Haematol* 2016;**3**:e64–e71.
48. Garcia MJ, Lookstein R, Malhotra R, Amin A, Blitz LR, Leung DA, Simoni EJ, Soukas PA. Endovascular management of deep vein thrombosis with rheolytic thrombectomy: final report of the prospective multicenter PEARL (peripheral use of angiojet rheolytic thrombectomy with a variety of catheter lengths) registry. *J Vasc Interv Radiol* 2015;**26**:777–785. Quiz 786.
49. Engelberger RP, Spirk D, Willenberg T, Alatri A, Do DD, Baumgartner I, Kucher N. Ultrasound-assisted versus conventional catheter-directed thrombolysis for acute iliofemoral deep vein thrombosis. *Circ Cardiovasc Interv* 2015;**8**.
50. Ray CE, Jr, Prochazka A. The need for anticoagulation following inferior vena cava filter placement: systematic review. *Cardiovasc Interv Radiol* 2008;**31**:316–324.
51. PREPIC Study Group. Eight-year follow-up of patients with permanent vena cava filters in the prevention of pulmonary embolism: the PREPIC (Prevention du Risque d'Embolie Pulmonaire par Interruption Cave) randomized study. *Circulation* 2005;**112**:416–422.
52. Mismetti P, Laporte S, Pellerin O, Ennezat PV, Couturaud F, Elias A, Falvo N, Meneveau N, Quere I, Roy PM, Sanchez O, Schmidt J, Seinturier C, Sevestre MA, Beregi JP, Tardy B, Lacroix P, Presles E, Leizorovicz A, Decousus H, Barral FG, Meyer G. Effect of a retrievable inferior vena cava filter plus anticoagulation vs anticoagulation alone on risk of recurrent pulmonary embolism: a randomized clinical trial. *JAMA* 2015;**313**:1627–1635.
53. Stein PD, Matta F, Keyes DC, Willyerd GL. Impact of vena cava filters on in-hospital case fatality rate from pulmonary embolism. *Am J Med* 2012;**125**:478–484.
54. Kearon C, Akl EA, Comerota AJ, Prandoni P, Bounameaux H, Goldhaber SZ, Nelson ME, Wells PS, Gould MK, Dentali F, Crowther M, Kahn SR. American College of Chest Physicians. Antithrombotic therapy for VTE disease: antithrombotic therapy and prevention of thrombosis, 9th ed: American College of Chest Physicians Evidence-Based Clinical Practice Guidelines. *Chest* 2012;**141**(2 Suppl):e419S–e494S.
55. Kahn SR, Shapiro S, Wells PS, Rodger MA, Kovacs MJ, Anderson DR, Tagalakis V, Houweling AH, Ducruet T, Holcroft C, Johri M, Solymoss S, Miron MJ, Yeo E, Smith R, Schulman S, Kassir J, Kearon C, Chagnon I, Wong T, Demers C, Hanmiah R, Kaatz S, Selby R, Rathbun S, Desmarais S, Opatrny L, Ortel TL, Ginsberg JS. Compression stockings to prevent post-thrombotic syndrome: a randomised placebo-controlled trial. *Lancet* 2014;**383**:880–888.
56. Brandjes DP, Buller HR, Heijboer H, Huisman MV, de Rijk M, Jagt H, ten Cate JW. Randomised trial of effect of compression stockings in patients with symptomatic proximal-vein thrombosis. *Lancet* 1997;**349**:759–762.
57. Kahn SR, Comerota AJ, Cushman M, Evans NS, Ginsberg JS, Goldenberg NA, Gupta DK, Prandoni P, Vedantham S, Walsh ME, Weitz JI, American Heart Association Council on Peripheral Vascular Disease CoCC, Council on C, Stroke N. The postthrombotic syndrome: evidence-based prevention, diagnosis, and treatment strategies: a scientific statement from the American Heart Association. *Circulation* 2014;**130**:1636–1661.
58. Partsch H, Blattler W. Compression and walking versus bed rest in the treatment of proximal deep venous thrombosis with low molecular weight heparin. *J Vasc Surg* 2000;**32**:861–869.
59. Righini M, Galanaud JP, Guennevez H, Brisot D, Diard A, Faisse P, Barrelier MT, Desnos CH, Jurus C, Pichot O, Martin M, Mazzolai L, Choquet C, Accassat S, Carrier M, Gal GL, Mermillod B, Laroche JP, Bounameaux H, Perrier A, Kahn S, Quéré I. Anticoagulant therapy for symptomatic distal deep vein thrombosis: The cactus randomized placebocontrolled trial. *J Thromb Haemost* 2015;**13**:50.
60. Palareti G. How I treat isolated distal deep vein thrombosis (IDDVT). *Blood* 2014;**123**:1802–1809.
61. Parisi R, Visona A, Camporese G, Verlato F, Lessiani G, Antignani PL, Palareti G. Isolated distal deep vein thrombosis: efficacy and safety of a protocol of treatment. Treatment of Isolated Calf Thrombosis (TICT) Study. *Int Angiol* 2009;**28**:68–72.

62. Schwarz T, Buschmann L, Beyer J, Halbritter K, Rastan A, Schellong S. Therapy of isolated calf muscle vein thrombosis: a randomized, controlled study. *J Vasc Surg* 2010;**52**:1246–1250.
63. Palareti G, Cosmi B, Lessiani G, Rodorigo G, Guazzaloca G, Brusi C, Valdre L, Conti E, Sartori M, Legnani C. Evolution of untreated calf deep-vein thrombosis in high risk symptomatic outpatients: the blind, prospective CALTHRO study. *Thromb Haemost* 2010;**104**:1063–1070.
64. Galanaud JP, Sevestre MA, Genty C, Kahn SR, Pernod G, Rolland C, Diard A, Dupas S, Jurus C, Diamand JM, Quere I, Bosson JL. Incidence and predictors of venous thromboembolism recurrence after a first isolated distal deep vein thrombosis. *J Thromb Haemost* 2014;**12**:436–443.
65. Sartori M, Migliaccio L, Favaretto E, Palareti G, Cosmi B. Two years outcome of isolated distal deep vein thrombosis. *Thromb Res* 2014;**134**:36–40.
66. Boutitie F, Pinede L, Schulman S, Agnelli G, Raskob G, Julian J, Hirsh J, Kearon C. Influence of preceding length of anticoagulant treatment and initial presentation of venous thromboembolism on risk of recurrence after stopping treatment: analysis of individual participants' data from seven trials. *BMJ* 2011;**342**:d3036.
67. Prandoni P, Noventa F, Ghirarduzzi A, Pengo V, Bernardi E, Pesavento R, Iotti M, Tormene D, Simioni P, Pagnan A. The risk of recurrent venous thromboembolism after discontinuing anticoagulation in patients with acute proximal deep vein thrombosis or pulmonary embolism. A prospective cohort study in 1,626 patients. *Haematologica* 2007;**92**:199–205.
68. Baglin T, Luddington R, Brown K, Baglin C. Incidence of recurrent venous thromboembolism in relation to clinical and thrombophilic risk factors: prospective cohort study. *Lancet* 2003;**362**:523–526.
69. Kovacs MJ, Kahn SR, Wells PS, Anderson DA, Chagnon IG, Solymoss, S, Crowther, M, Perrier, A, Ramsay, T, Betancourt, MT, White, RH, Vickers, L, Rodger, MA. Patients with a first symptomatic unprovoked deep vein thrombosis are at higher risk of recurrent venous thromboembolism than patients with a first unprovoked pulmonary embolism. *J Thromb Haemost* 2010;**8**:1926–1932.
70. Kearon C, Akl EA, Ornelas J, Blaivas A, Jimenez D, Bounameaux H, Huisman M, King CS, Morris TA, Sood N, Stevens SM, Vintch JR, Wells P, Woller SC, Moores L. Antithrombotic therapy for VTE disease. CHEST guideline and expert panel report. *Chest* 2016;**149**:315–352.
71. Kyrle PA, Eichinger S. Clinical scores to predict recurrence risk of venous thromboembolism. *Thromb Haemost* 2012;**108**:1061–1064.
72. Loewen P, Dahri K. Risk of bleeding with oral anticoagulants: an updated systematic review and performance analysis of clinical prediction rules. *Ann Hematol* 2011;**90**:1191–1200.
73. Burgess S, Crown N, Louzada ML, Dresser G, Kim RB, Lazo-Langner A. Clinical performance of bleeding risk scores for predicting major and clinically relevant non-major bleeding events in patients receiving warfarin. *J Thromb Haemost* 2013;**11**:1647–1654.
74. Palareti G, Cosmi B, Legnani C, Antonucci E.D., Micheli, V Ghirarduzzi, A Poli, D Testa, S, Tosetto, A Pengo, V Prandoni, P, DULCIS (D-dimer and Ultrasonography in Combination Italian Study) Investigators. D-dimer to guide the duration of anticoagulation in patients with venous thromboembolism: a management study. *Blood* 2014;**124**:196–203.
75. Kearon C, Spencer FA, O'keeffe D, Parpia S, Schulman S, Baglin T, Stevens SM, Kaatz S, Bauer KA, Douketis JD, Lentz SR, Kessler CM, Moll S, Connors JM, Ginsberg JS, Spadafora L, Julian JA. D-dimer testing to select patients with a first unprovoked venous thromboembolism who can stop anticoagulant therapy: a cohort study. *Ann Intern Med* 2015;**162**:27–34.
76. Kearon C, Parpia S, Spencer FA, Baglin T, Stevens SM, Bauer KA, Lentz SR, Kessler CM, Douketis JD, Moll S, Kaatz S, Schulman S, Connors JM, Ginsberg JS, Spadafora L, Liaw P, Weitz JI, Julian JA. D-dimer levels and recurrence in patients with unprovoked VTE and a negative qualitative D-dimer test after treatment. *Thromb Res* 2016;**146**:119–125.
77. Schulman S, Granqvist S, Holmstrom M, Carlsson A, Lindmarker P, Nicol P, Eklund SG, Nordlander S, Larfars G, Leijd B, Linder O, Loogna E. The duration of oral anticoagulant therapy after a second episode of venous thromboembolism. The Duration of Anticoagulation Trial Study Group. *N Engl J Med* 1997;**336**:393–398.
78. Kearon C, Gent M, Hirsh J, Weitz J, Kovacs MJ, Anderson DR, Turpie AG, Green D, Ginsberg JS, Wells P, MacKinnon B, Julian JA. A comparison of three months of anticoagulation with extended anticoagulation for a first episode of idiopathic venous thromboembolism. *N Engl J Med* 1999;**340**:901–907.
79. Agnelli G, Prandoni P, Santamaria MG, Bagatella P, Iorio A, Bazzan M, Moia M, Guazzaloca G, Bertoldi A, Tomasi C, Scannapieco G, Ageno W, Warfarin Optimal Duration Italian Trial Investigators. Three months versus one year of oral anticoagulant therapy for idiopathic deep venous thrombosis. *N Engl J Med* 2001;**345**:165–169.
80. Agnelli G, Prandoni P, Becattini C, Silingardi M, Taliani MR, Miccio M, Imberti D, Poggio R, Ageno W, Pogliani E, Porro F, Zonzin P, Warfarin Optimal Duration Italian Trial Investigators. Extended oral anticoagulant therapy after a first episode of pulmonary embolism. *Ann Intern Med* 2003;**139**:19–25.
81. Castellucci LA, Cameron C, Le Gal G, Rodger MA, Coyle D, Wells PS, Clifford T, Gandara E, Wells G, Carrier M. Efficacy and safety outcomes of oral anticoagulants and antiplatelet drugs in the secondary prevention of venous thromboembolism: systematic review and network meta-analysis. *BMJ* 2013;**347**:f5133.
82. Kearon C, Ginsberg JS, Kovacs MJ, Anderson DR, Wells P, Julian JA, MacKinnon B, Weitz JI, Crowther MA, Dolan S, Turpie AG, Geerts W, Solymoss S, van Nguyen P, Demers C, Kahn SR, Kassis J, Rodger M, Hambleton J, Gent M, Extended Low-Intensity Anticoagulation For Thrombo-Embolic I. Comparison of low-intensity warfarin therapy with conventional-intensity warfarin therapy for long-term prevention of recurrent venous thromboembolism. *N Engl J Med* 2003;**349**:631–639.
83. Schulman S, Kearon C, Kakkar AK, Schellong S, Eriksson H, Baanstra D, Kvanme AM, Friedman J, Mismetti P, Goldhaber SZ, RE-MEDY Trials Investigators, RE-SONATE Trials Investigators. Extended use of dabigatran, warfarin, or placebo in venous thromboembolism. *N Engl J Med* 2013;**368**:709–718.
84. Bauersachs R, Berkowitz SD, Brenner B, Buller HR, Decousus H, Gallus AS, Lensing AW, Misselwitz F, Prins MH, Raskob GE, Segers A, Verhamme P, Wells P, Agnelli G, Bounameaux H, Cohen A, Davidson BL, Piovella F, Schellong S, The EINSTEIN Investigators. Oral rivaroxaban for symptomatic venous thromboembolism. *N Engl J Med* 2010;**363**:2499–2510.
85. Weitz JI, Lensing AW, Prins MH, Bauersachs R, Beyer-Westendorf J, Bounameaux H, Brighton TA, Cohen AT, Davidson BL, Decousus H, Freitas MC, Holberg G, Kakkar AK, Haskell L, van Bellen B, Pap AF, Berkowitz SD, Verhamme P, Wells PS, Prandoni P, EINSTEIN CHOICE Investigators. Rivaroxaban or Aspirin for Extended Treatment of Venous Thromboembolism. *N Engl J Med* 2017; in press.
86. Agnelli G, Buller HR, Cohen A, Curto M, Gallus AS, Johnson M, Porcari A, Raskob GE, Weitz JI, AMPLIFY-EXT Investigators. Apixaban for extended treatment of venous thromboembolism. *N Engl J Med* 2013;**368**:699–708.
87. Raskob G, Ageno W, Cohen AT, Brekelmans MP, Grosso MA, Segers A, Meyer G, Verhamme P, Wells PS, Lin M, Winters SM, Weitz JI, Buller HR. Extended duration of anticoagulation with edoxaban in patients with venous thromboembolism: a post-hoc analysis of the Hokusai-VTE study. *Lancet Haematol* 2016;**3**:e228–e236.
88. Ageno W, Mantovani LG, Haas S, Kreutz R, Monje D, Schneider J, van Eickels M, Gebel M, Zell E, Turpie AG. Safety and effectiveness of oral rivaroxaban versus standard anticoagulation for the treatment of symptomatic deep-vein thrombosis (XALIA): an international, prospective, non-interventional study. *Lancet Haematol* 2016;**3**:e12–e21.
89. Becattini C, Agnelli G, Schenone A, Eichinger S, Bucherini E, Silingardi M, Bianchi M, Moia M, Ageno W, Vandelli MR, Grandone E, Prandoni P, WARFASA Investigators. Aspirin for preventing the recurrence of venous thromboembolism. *N Engl J Med* 2012;**366**:1959–1967.
90. Brighton TA, Eikelboom JW, Mann K, Mister R, Gallus A, Ockelford P, Gibbs H, Hague W, Xavier D, Diaz R, Kirby A, Simes J, Investigators A. Low-dose aspirin for preventing recurrent venous thromboembolism. *N Engl J Med* 2012;**367**:1979–1987.
91. Simes J, Becattini C, Agnelli G, Eikelboom JW, Kirby AC, Mister R, Prandoni P, Brighton TA, Investigators IS. Aspirin for the prevention of recurrent venous thromboembolism: the INSPIRE collaboration. *Circulation* 2014;**130**:1062–1071.
92. Andreozzi GM, Bignamini AA, Davi G, Palareti G, Matuska J, Holy M, Pawlaczyk-Gabriel K, Dzapina A, Sokurenko GY, Didenko YP, Andrei LD, Lessiani G, Visona A. Sulodexide for the prevention of recurrent venous thromboembolism: the sulodexide in secondary prevention of recurrent deep vein thrombosis (SURVET) study: a multicenter, randomized, double-blind, placebo-controlled trial. *Circulation* 2015;**132**:1891–1897.
93. Neglen P, Hollis KC, Olivier J, Raju S. Stenting of the venous outflow in chronic venous disease: long-term stent-related outcome, clinical, and hemodynamic result. *J Vasc Surg* 2007;**46**:979–990.
94. Delis KT, Bjarnason H, Wennberg PW, Rooke TW, Gloviczki P. Successful iliac vein and inferior vena cava stenting ameliorates venous claudication and improves venous outflow, calf muscle pump function, and clinical status in post-thrombotic syndrome. *Ann Surg* 2007;**245**:130–139.
95. Kucher N. Clinical practice. Deep-vein thrombosis of the upper extremities. *N Engl J Med* 2011;**364**:861–869.
96. Grant JD, Stevens SM, Woller SC, Lee EW, Kee ST, Liu DM, Lohan DG, Elliott CG. Diagnosis and management of upper extremity deep-vein thrombosis in adults. *Thromb Haemost* 2012;**108**:1097–1108.
97. Thompson JF, Winterborn RJ, Bays S, White H, Kinsella DC, Watkinson AF. Venous thoracic outlet compression and the Paget-Schroetter syndrome: a review and recommendations for management. *Cardiovasc Interv Radiol* 2011;**34**:903–910.
98. Constans J, Salmi LR, Sevestre-Pietri MA, Perusat S, Nguon M, Degeilh M, Labarere J, Gattoliat O, Boulon C, Laroche JP, Le Roux P, Pichot O, Quere I,

- Conri C, Bosson JL. A clinical prediction score for upper extremity deep venous thrombosis. *Thromb Haemost* 2008;**99**:202–207.
99. Sartori M, Migliaccio L, Favaretto E, Cini M, Legnani C, Palareti G, Cosmi B. D-dimer for the diagnosis of upper extremity deep and superficial venous thrombosis. *Thromb Res* 2015;**135**:673–678.
 100. Kleinjan A, Di Nisio M, Beyer-Westendorf J, Camporese G, Cosmi B, Ghirarduzzi A, Kamphuisen PW, Otten HM, Porreca E, Aggarwal A, Brodmann M, Guglielmi MD, Iotti M, Kaasjager K, Kamvissi V, Lerede T, Marschang P, Meijer K, Palareti G, Rickles FR, Righini M, Rutjes AW, Tonello C, Verhamme P, Werth S, van Wissen S, Buller HR. Safety and feasibility of a diagnostic algorithm combining clinical probability, d-dimer testing, and ultrasonography for suspected upper extremity deep venous thrombosis: a prospective management study. *Ann Int Med* 2014;**160**:451–457.
 101. Di Nisio M, Van Sluis GL, Bossuyt PM, Buller HR, Porreca E, Rutjes AW. Accuracy of diagnostic tests for clinically suspected upper extremity deep vein thrombosis: a systematic review. *J Thromb Haemost* 2010;**8**:684–692.
 102. Rosa-Salazar V, Trujillo-Santos J, Diaz Peromingo JA, Apollonio A, Sanz O, Maly R, Munoz-Rodriguez FJ, Serrano JC, Soler S, Monreal M, Investigators R. A prognostic score to identify low-risk outpatients with acute deep vein thrombosis in the upper extremity. *J Thromb Haemost* 2015;**13**:1274–1278.
 103. Ferro JM, Canhao P, Stam J, Boussier MG, Barinagarrementeria F, Investigators I. Prognosis of cerebral vein and dural sinus thrombosis: results of the International Study on Cerebral Vein and Dural Sinus Thrombosis (ISCVT). *Stroke* 2004;**35**:664–670.
 104. Wasay M, Bakshi R, Bobustic G, Kojan S, Sheikh Z, Dai A, Cheema Z. Cerebral venous thrombosis: analysis of a multicenter cohort from the United States. *J Stroke Cerebrovasc Dis* 2008;**17**:49–54.
 105. Thatipelli MR, McBane RD, Hodge DO, Wysokinski WE. Survival and recurrence in patients with splanchnic vein thromboses. *Clin Gastroenterol Hepatol* 2010;**8**:200–205.
 106. Ageno W, Riva N, Schulman S, Bang SM, Sartori MT, Grandone E, Beyer-Westendorf J, Barillari G.D., Minno, MN, Dentali, F, IRSVT study group. Antithrombotic treatment of splanchnic vein thrombosis: results of an international registry. *Semin Thromb Hemost* 2014;**40**:99–105.
 107. Khorana AA, Kuderer NM, Culakova E, Lyman GH, Francis CW. Development and validation of a predictive model for chemotherapy-associated thrombosis. *Blood* 2008;**111**:4902–4907.
 108. Pabinger I, Thaler J, Ay C. Biomarkers for prediction of venous thromboembolism in cancer. *Blood* 2013;**122**:2011–2018.
 109. Khorana AA, Dalal M, Lin J, Connolly GC. Incidence and predictors of venous thromboembolism (VTE) among ambulatory high-risk cancer patients undergoing chemotherapy in the United States. *Cancer* 2013;**119**:648–655.
 110. Farge D, Bounameaux H, Brenner B, Cajfinger F, Debourdeau P, Khorana AA, Pabinger I, Solymoss S, Douketis J, Kakkar A. International clinical practice guidelines including guidance for direct oral anticoagulants in the treatment and prophylaxis of venous thromboembolism in patients with cancer. *Lancet Oncol* 2016;**17**:e452–e466.
 111. Vedovati MC, Germini F, Agnelli G, Becattini C. Direct oral anticoagulants in patients with VTE and cancer: a systematic review and meta-analysis. *Chest* 2015;**147**:475–483.
 112. Nelson-Piercy C, MacCallum P, Mackillop L. Reducing the risk of thrombosis and embolism during pregnancy and the puerperium (Green-top guideline no. 37a). *R Coll Obstetr Gynaecol* 2015;1–40.
 113. Le Moigne E, Genty C, Meunier J, Arnoult AC, Righini M, Bressollette L, Bosson JL, Le Gal G. Validation of the LEFT score, a newly proposed diagnostic tool for deep vein thrombosis in pregnant women. *Thromb Res* 2014;**134**:664–667.
 114. Le Gal G, Prins AM, Righini M, Bohec C, Lacut K, Germain P, Vergos JC, Kaczmarek R, Guais B, Collet M, Bressollette L, Oger E, Mottier D. Diagnostic value of a negative single complete compression ultrasound of the lower limbs to exclude the diagnosis of deep venous thrombosis in pregnant or postpartum women: a retrospective hospital-based study. *Thromb Res* 2006;**118**:691–697.
 115. Le Gal G, Kercret G, Ben Yahmed K, Bressollette L, Robert-Ebadi H, Riberdy L, Louis P, Delluc A, Labalette ML, Baba-Ahmed M, Bounameaux H, Mottier D, Righini M. Diagnostic value of single complete compression ultrasonography in pregnant and postpartum women with suspected deep vein thrombosis: prospective study. *BMJ* 2012;**344**:e2635.
 116. Bates SM, Greer IA, Middeldorp S, Veenstra DL, Prabulos AM, Vandvik PO. VTE, thrombophilia, antithrombotic therapy, and pregnancy: antithrombotic therapy and prevention of thrombosis, 9th ed: American College of Chest Physicians Evidence-Based Clinical Practice Guidelines. *Chest* 2012;**141**(2 Suppl):e691S–e736S.
 117. Thomsen A, Greer I. Thromboembolic disease in pregnancy and the puerperium: acute management (Green-top guideline no. 37b). *R Coll Obstetr Gynaecol* 2015;1–32.
 118. Chan WS, Spencer FA, Lee AY, Chunil S, Douketis JD, Rodger M, Ginsberg JS. Safety of withholding anticoagulation in pregnant women with suspected deep vein thrombosis following negative serial compression ultrasound and iliac vein imaging. *CMAJ* 2013;**185**:E194–E200.
 119. Romualdi E, Dentali F, Rancan E, Squizzato A, Steidl L, Middeldorp S, Ageno W. Anticoagulant therapy for venous thromboembolism during pregnancy: a systematic review and a meta-analysis of the literature. *J Thromb Haemost* 2013;**11**:270–281.
 120. Bauersachs RM. Treatment of venous thromboembolism during pregnancy. *Thromb Res* 2009;**123**(Suppl. 2):S45–S50.
 121. Bauersachs RM, Dudenhausen J, Faridi A, Fischer T, Fung S, Geisen U, Harenberg J, Herchenhan E, Keller F, Kemkes-Matthes B, Schinzel H, Spannagl M, Thaler CJ. Risk stratification and heparin prophylaxis to prevent venous thromboembolism in pregnant women. *Thromb Haemost* 2007;**98**:1237–1245.